

Supplement to the January 2006 Issue of

WOUNDS

A Compendium of Clinical Research and Practice

Clinical Experience with a New, Stable, Super-Oxidized Water in Wound Treatment

A look at the science and clinical results of a novel,
super-oxidized antiseptic solution
in the treatment of wounds



Table of Contents



Super-Oxidized Dermacyn in Lower-Extremity Wounds

Introduction and early experiencepage 3

David E. Allie, MD
Cardiovascular Institute of the South
Lafayette, LA



The Science Behind Stable, Super-Oxidized Water

Exploring the various applications of super-oxidized solutions.....page 7

Andrés A. Gutiérrez, MD, PhD
Oculus Innovative Sciences
Petaluma, California



Advanced Wound Care with Stable, Super-Oxidized Water

A look at how combination therapy can optimize wound healing.....page 11

Tom A. Wolvos, MD, FACS
Scottsdale Healthcare Wound Management Services
Scottsdale, Arizona



Treating Diabetic Foot Ulcers with Super-Oxidized Water

A look at advances in this pH-neutral, non-toxic treatmentpage 14

Luca Dalla Paola, MD
Diabetic Foot Department, Foot & Ankle Clinic
Abano Terme Hospital, Abano Terme, Italy



Reducing Bacterial Infectious Complications from Burn Wounds

A look at the use of Oculus Microcyn60 to treat wounds in Mexicopage 17

Ariel Miranda Altamirano, MD
Pediatric Burn Unit
Hospital Civil, Guadalajara, Mexico



Super-Oxidized Microcyn Technology in Lower-Extremity Wounds

Introduction and early experience

David E. Allie, MD

When considering the spectrum of chronic limb wounds in which infection plays a clinical role, critical limb ischemia (CLI), diabetic foot ulcers (DFUs), below-knee amputations (BKA), methicillin-resistant *Staphylococcus aureus* (MRSA), and chronic venous insufficiency (CVI) are sure to come to mind. The role of infection in these conditions may range from minor to severe, but it likely plays a significant role in most cases. This supplement will introduce a novel, local, super-oxidized antiseptic solution, Microcyn® Technology (Oculus Innovative Sciences, Petaluma, Calif), and review the science surrounding its unique mechanism of action and the early clinical experiences from centers in Italy, Mexico, and the United States. The clinical and economical impact of acute and chronic infections in lower-extremity wounds is certainly substantial, but this impact is dwarfed when considering the overall clinical and economical global healthcare impact of infection across the entire spectrum of acute to chronic skin wounds (eg, pressure ulcers, burns, trauma, surgical infections, acne) and acute and chronic respiratory infections (eg, sinusitis, bronchitis, pneumonitis, bird flu).

The Reality of Infection and Limb Loss

Between 220,000 and 240,000 lower-extremity amputations are performed in the United States and Europe yearly for arterial insufficiency, diabetes, and CLI.¹⁻⁵ In the United States, the amputation rate has increased from 19 to 30 per 100,000 persons/years over the last 2 decades, primarily due to an increase in diabetes and advancing age.⁶⁻⁷ In patients over 85 years of age, an amputation rate of 140 per 100,000 persons/year has been reported with primary

amputation (PA) still carrying an excessively high mortality rate of 13–17%.⁷⁻⁹ In the highest risk patients,¹⁰ 30-day perioperative mortality after amputation can range from 4–30% and morbidity from 20–37%, because many end-stage CLI patients will suffer from infection, sepsis, and progressive renal insufficiency. Successful rehabilitation after

Successful rehabilitation after below-knee amputation is achieved in less than two-thirds of patients.

BKA is achieved in less than two-thirds of patients; after above-the-knee amputations, that fraction is less than one-half of patients. Overall, less than 50% of all patients requiring amputation ever achieve full mobility.¹¹⁻¹⁵ Multiple reports have documented the poor overall prognosis for the CLI patient with mortality rates greater than 50% after 3 years and twice the mortality rate after BKA versus limb salvage.^{10,16} Clearly, the clinical impact of CLI and amputations is staggering, and the overall role of infection in limb loss is poorly understood and certainly under appreciated.

Taking the Economical Standpoint

The total cost of treating CLI in the United States is estimated at \$10–20 billion per year.³ It is estimated that just a 25%

reduction of amputations could save \$2.9–3.0 billion in US healthcare expenditures.³ Further economic data supporting limb salvage include the known higher costs of amputations and related periprocedural rehabilitation as compared to limb salvage. Additionally, the annual cost of follow-up or long-term care and treatment for an amputee has been estimated at approximately \$49,000 if he or she remains at home and \$90,000–100,000 if he or she becomes nursing-home bound (15–20% of total amputees) versus \$600 after limb salvage.^{3,10,16–18}

More than 5 million patients suffer from chronic wounds in the US each year at a total cost of greater than \$20 billion a year.^{19,20} The costs of treating pressure ulcers alone are greater than \$1 billion yearly, and 1.5 to 3 million US adults in long-term care settings yearly require treatment.²¹ Infection unquestionably plays a large clinical and economical role in chronic wound care, and

It is likely that the overall costs of infection in the global healthcare picture are greater than \$100 billion yearly.

antibiotics have associated complications, side effects, and significant economical costs.

The national daily hospital cost per Medicare patient averages \$2,360; therefore, any strategy to rapidly sterilize wounds, decrease IV and oral antibiotic use, decrease hospitalizations, and facilitate time to wound healing would have a significant clinical and economical impact.²² It is likely that the overall costs of infection in the global healthcare picture are greater than \$100 billion yearly. The initial data and experiences would suggest wound treatment with Dermacyn (formulated with Microcyn Technology) might favorably impact wound care, especially in achieving more rapid wound sterilization therefore facilitating healing. However, prospective,

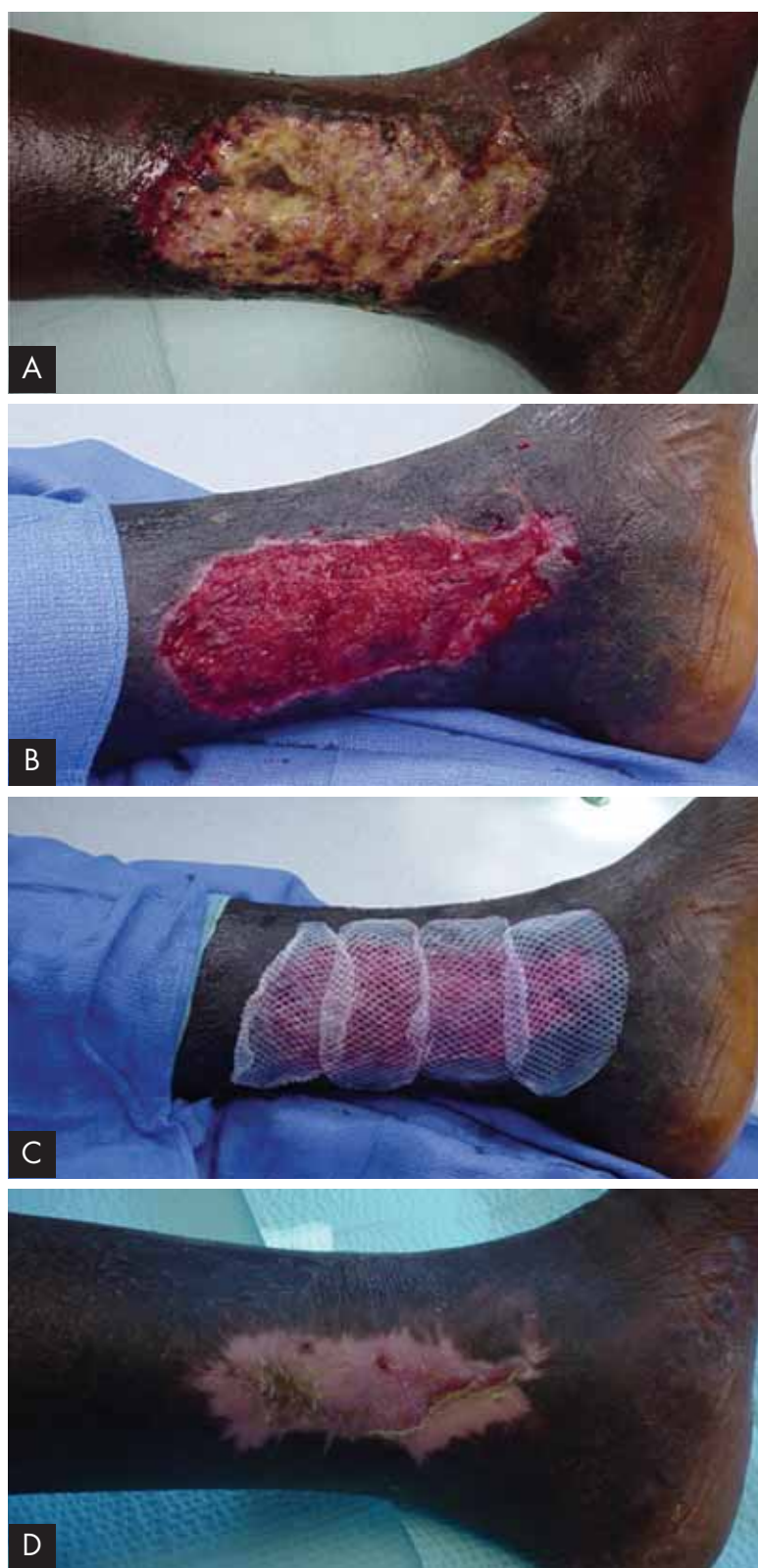

Figure 1. Infected chronic venous insufficiency ulcer of 1-year duration (A). Noninfected healthy wound bed after Dermacyn wound sterilization 3 times daily and minor debridement (B). Multiple bilayered cell therapy applied as adjuvant treatment (C). Complete healing at 2 months (D).

randomized, multicenter evidence-based data will be necessary to scientifically assess the merits of this promising emerging therapy in wound care.

The author's early safety and feasibility experience (4 months) with Dermacyn has been favorable in treating a variety of complex extremity wounds with infection (n = 40) including CLI (n = 28), CVI (n = 6), trauma (n = 2), and surgical dehiscence (n = 4). Despite the limitations of this nonrandomized, retrospective, small series analysis, there were no Dermacyn-related complications. Limb salvage rate was 100%. All wounds healed (mean = 23 days), and several adjuvant therapies were utilized including bio-engineered skin (Apligraf, Organogenesis, Inc., Canton, Mass, n = 8), negative pressure wound therapy (VAC Therapy, Kinetic Concepts, Inc., San Antonio, Tex, n = 4), and local extremity oxygen replacement (LEXOR, n = 4). Dermacyn treatment was found to be safe, simple, and well accepted by patients. Rapid clinical sterilization of all wounds facilitated overall wound healing and wound preparation for more definitive adjuvant wound therapies including Apligraf (Figure 1). Active infection is a known contraindication to utilization for Apligraf and VAC. Other clinical findings in this series included a decrease in antibiotic (IV and oral) administration and decrease in hospitalizations for wound treatment.

A Review of What's to Come

In this supplement, which is a reproduction of a wound care symposium presented at the October 2005 New Cardiovascular Horizons and Management of the Diabetic Foot Conference in Miami, Fla, several noted physicians will present their early experience with super-oxidized Microcyn Technology in a variety of clinical scenarios including DFUs, CVI ulcers, complex traumatic wounds, and burns. There are more than 18 million US patients suffering from diabetes, which is now the sixth leading cause of death and major contributor in more than 50% of all amputations.²³ Approximately 80–85% of all amputations are preceded by an ulcer (eg, ischemic, DFU, CVI, mixed), and deep infections and osteomyelitis undoubtedly play a significant role in many amputations.²⁴

Dr. Andrés Gutiérrez will discuss the science and mechanism of action of Microcyn Technology in achieving rapid wound sterilization without apparent harm to normal cells. He will also present interesting and impressive data from Mexico in treating a wide variety of acute and chronic wounds and discuss plans for further randomized, perspective data collection and analysis.

Dr. Tom Wolvos, a general surgeon and wound care specialist, will present his experience with Dermacyn Wound Care in a variety of complex, advanced wounds including a unique experience in combining Dermacyn with negative pressure wound therapy with the VAC and the VAC InStill, which allows the instillation of fluids into the wound. Advanced wounds reported by Dr. Wolvos will include large decubitus ulcers, large post-op wound dehiscence with exposed abdominal wall mesh, and complex traumatic and post-op surgical wounds.

Dr. Luca Dalla Paola, an endocrinologist and wound care specialist, will present his experience with Dermacyn from the Albano Terme Hospital in Albano Terme, Italy. Dr. Paola will present data in advanced CLI patients who required complex revascularization, surgical debridement, and control of infec-

Approximately 80–85% of all amputations are preceded by an ulcer (eg, ischemic, DFU, CVI, mixed), and deep infections and osteomyelitis undoubtedly play a significant role in many amputations.²⁴

tion and diabetes to achieve limb salvage (in 218 patients). The Dermacyn-treated group experienced less major surgical procedures and amputations with shorter times to healing (45 days vs. 58 days) than the control group. The control group experienced 16% adverse skin reactions, while the Dermacyn group had no adverse skin reactions.

Thermal injury presents a special, atypical, acute wound that carries significant clinical and societal impact, especially in the pediatric patient population. **Dr. Ariel Miranda Altamirano**, a plastic surgeon at the University of Guadalajara and Chief of the Hospital Civil Pediatric Burn Unit, presents that facility's impressive results utilizing Oculus Microcyn60 in a wide variety of pediatric burn patients.

Other Issues to Consider

Antibiotic resistance has become a major healthcare problem in treating many hospitalized and outpatient individuals. It is particularly problematic in DFUs. Specifically, MRSA

pathogens have been associated with a significantly increasing incidence, increased hospital stay and costs, and poorer clinical outcomes with higher amputation rates and higher mortality rates.^{25,26} Vancomycin is increasingly less effective against MRSA, resulting in the emergence of new antibiotics that are expensive and have significant risks. Clearly, any local topical solution that would have excellent efficacy versus MRSA and other bacterial and nonbacterial pathogens with minimal complications would offer a potential significant improvement over the current treatments for wound infection and wound healing. ■

References

1. US Department of Health and Human Services. National Center for Health Statistics. National Hospital Discharge Survey: Annual Summary with Det Arnold Publication;1996:162-175.
9. Hobson RW 2nd, Lynch TG, Jamil Z, et al. Results of revascularization and amputation in severe lower extremity ischemia: a five-year clinical experience. *J Vasc Surg.* 1985;2(1):174-185.
10. Dormandy JA, Rutherford RB. Management of peripheral arterial disease (PAD). TASC Working Group. TransAtlantic Inter-Society Consensus (TASC). *J Vasc Surg.* 2000;31(1 Pt 2):S1-S296.
11. Gregg RO. Bypass or amputation? Concomitant review of bypass arterial grafting and major amputations. *Am J Surg.* 1985;149(3):397-402.
12. Mackey WC, McCullough JL, Conlon TP, et al. The costs of surgery for limb-threatening ischemia. *Surgery.*1986;99(1):26-35.
13. Raviola CA, Nichter LS, Baker JD, et al. Cost of treating advanced leg ischemia. Bypass graft vs primary amputation. *Arch Surg.* 1988;123(4):495-496.
14. Paaske WP, Laustsen J. Femorodistal bypass grafting: quality of life and socioeconomic aspects. *Eur J Vasc Endovasc Surg.* 1995;10(2):226-230.
15. Wolfe JH, Wyatt MG. Critical and subcritical ischaemia. *Eur J Vasc Endovasc Surg.* 1997;13(6):578-582.
16. Pentecost MJ, Criqui MH, Dorros G, et al. Guidelines for peripheral percutaneous transluminal angioplasty of the abdominal aorta and lower extremity vessels. A statement for health professionals from a special writing group of the Councils on Cardiovascular Radiology, Arteriosclerosis, Cardio-Thoracic and Vascular Surgery, Clinical Cardiology, and Epidemiology and Prevention, the American Heart Association. *Circulation.* 1994;89(1):511-531.
17. Muradin GS, Myriam Hunink MG. Cost and patency rate targets for the development of endovascular devices to treat femoropopliteal arterial disease. *Radiology.* 2001;218(2):464-469.
18. Muradin GS, Bosch JL, Stijnen T, Hunink MG. Balloon dilation and stent implantation for treatment of femoropopliteal arterial disease: meta-analysis. *Radiology.* 2001;221(1):137-145.
19. Ramsey SD, Newton K, Blough D, et al. Incidence, outcomes, and cost of foot ulcers in patients with diabetes. *Diabetes Care.* 1999;22(3):382-387.
20. Edmonds ME, Blundell MP, Morris ME, et al. Improved survival of the diabetic foot: the role of a specialized foot clinic. *Q J Med.* 1986;60(232):763-771.
21. Dang CN, Prasad YD, Boulton AJ, Jude EB. Methicillin-resistant *Staphylococcus aureus* in the diabetic foot clinic: a worsening problem. *Diabet Med.* 2003;20(2):159-161.
22. Wagner A, Reike H, Angelkort B. Highly resistant pathogens in patients with diabetic foot syndrome with special reference to methicillin-resistant *Staphylococcus aureus* infections. *Dtsch Med Wochenschr.* 2001;126(48):1353-1356.
23. Theta Reports. Advanced wound care biologics: world market analysis. August 1, 2002. Available at: <http://www.marketresearch.com/product/display.asp?productid=801249&SID=84612660-339803724-290187384>. Accessed December 19, 2005.
24. Motta G. "The first 60 days of PPS: managing wound care medical supplies." The Remington Report. Nov/Dec.2000. <http://www.woundcare.org/newsvol5n3/ar10.htm>.
25. Lyder CH, Shannon R, Empleo-Frazier O, et al. A comprehensive program to prevent pressure ulcers in long-term care: exploring costs and outcomes. *Ostomy Wound Manage.* 2002;48(4):52-62.
26. US Census Bureau. *Statistical Abstract of the United States: 1996.* 116th ed. US Department of Commerce, Washington, DC; 1996.



The Science Behind Stable, Super-Oxidized Water

Exploring the various applications of super-oxidized solutions

Andrés A. Gutiérrez, MD, PhD

Electrolysis is a process in which an electric current is passed through water or a solution, generating various reactive chemical species that depend on the solute and the electrode material used for producing electrolysis. Most super-oxidized solutions (or waters) are electrochemically processed aqueous solutions manufactured from pure water and sodium chloride. In general, the concept of electrolysis is relatively simple: tap water is purified through reverse-osmosis and USP-grade sodium chloride is added before being submitted to an electric field. During this electrolysis process, molecules are pulled apart in a chamber with positive and negative poles, and hypochlorite/ous species and free radicals are formed. The final result is a blend of reactive species of chlorine and oxygen with numerous applications in medicine and disinfection. This article will review some of these applications as they apply to wound care.

The Dawn of a New Solution

Researchers from the United States, United Kingdom, and Japan have investigated super-oxidized solutions as disinfectants for instruments and hard, inanimate surfaces in hospitals.¹⁻³ For example, super-oxidized solutions have decreased the time, toxicity, and costs of material disinfection in endoscopes.⁴ The literature also describes the use of super-oxidized solutions on humans for various indications including the treatment of infectious skin defects or ulcers, mediastinal irrigation after open-heart surgery, and treatment of peritonitis and intraperitoneal abscesses.⁵⁻⁸ Super-oxidized solutions have also been recommended for hand washing in medical personnel.⁹

Unfortunately, the instability and corrosion potential of the first solutions completely destroyed the market at the end of the

1990s. At that time, Oculus Innovative Sciences generated Microcyn[®] Technology (a super-oxidized, non-toxic, non-irritating, no-rinse dermal wound irrigant) that could be used for wound care treatment. The electrolysis cells used to produce this super-oxidized solution are significantly different from those previously designed by other companies. This solu-

Researchers from the United States, United Kingdom, and Japan have investigated super-oxidized solutions as disinfectants for instruments and hard, inanimate surfaces in hospitals.¹⁻³

tion is produced by the electrolysis of water and USP-grade sodium chloride. The end product is a pH-neutral, super-oxidized solution with a longer shelf life (>12 months) than any other super-oxidized solution tested to date. It is intended for the topical treatment of infective chronic and acute wounds. Most importantly, it is non-irritating and non-sensitizing.

In-Vitro Antimicrobial Activity

The first results of the antimicrobial activity of Microcyn Technology have recently been published by independent researchers.¹¹ In addition, many other tests have been conducted by third-party laboratories in accordance with Good

Table 1: Summary of Toxicology Studies

Type of Study	Standard	Species
Acute Skin Irritation	ISO 10993-01:2002	Rabbit
Acute Dermal Toxicity	US EPA OPPTS 870.1200	Rabbit
Skin Sensitization	US EPA OPPTS 870.2600	Guinea Pig
Acute Systemic Toxicity	US EPA OPPTS 870	Mouse
Acute Oral Toxicity	US EPA OPPTS 870.1100	Rat
Ocular Irritation	ISO 10993-10:2002	Rabbit
Acute Inhalation Toxicity	EPA OPPTS 870.1300	Rat
Genotoxicity Micronucleus Test	OECD Guideline #474 ISO 10993-3:2003	Mouse

Laboratory Practices (GLP), as specified in 21CFR Part 58. Some examples are described.

Bactericidal and fungicidal activity (suspension tests). An *in-vitro* time kill evaluation was performed using Microcyn Technology versus challenge suspensions of 50 different

A major concern when using super-oxidized solutions is the potential induction of DNA oxidation, accelerated aging, and genotoxicity.

microorganism strains (25 American Type Culture Collection [ATCC] strains and 25 clinical isolates of those same species) as described in the Tentative Final Monograph.¹² After exposure for 30 seconds, there was a reduction of the bacterial load $>5 \log_{10}$ in the following samples: *Pseudomonas aeruginosa*, *Escherichia coli*, *Enterococcus hirae*, *Acinetobacter baumannii*, *Acinetobacter* species, *Bacteroides fragilis*, *Enterobacter aerogenes*, *Enterococcus faecalis*, vancomycin-resistant enterococcus (VRE), *Haemophilus influenzae*, *Klebsiella oxytoca*, *Klebsiella pneumoniae*, *Micrococcus luteus*, *Proteus mirabilis*, *Serratia marcescens*, *Staphylococcus aureus*, *Staphylococcus epidermidis*, *Staphylococcus haemolyticus*, *Staphylococcus pyogenes*, and *Candida albicans* (BioScience Labs, Bozeman, Mont.).

Bactericidal and fungicidal activity (carrier tests). In various tests, the bactericidal and fungicidal properties of Microcyn Technology have been tested in accordance to EPA DIS/TSS guidelines. Under these conditions, Microcyn Technology has totally inhibited the growth of the following microorganisms: *Mycobacterium bovis* (OT #105401) in 5 minutes; *P. aeruginosa* (ATCC #15442), *S. aureus* (ATCC #6538), *Salmonella choleraesuis* (ATCC #10708), methicillin-resistant *S. aureus* (MRSA, ATCC #33592); and *Trichophyton mentagrophytes* (ATCC #9533) in 10 minutes; and vancomycin-resistant *Enterococcus faecalis* (VRE, ATCC #51299) in 15 minutes (ATS Labs, Eagan, Minn.).

Virucidal activity. Microcyn Technology was tested to determine the virucidal characteristics against the human immunodeficiency virus type 1 (HIV-1) strain HTLV-III B in accordance with the United States EPA DIS/TSS-07 guidelines. In an independent study, the reduction in viral titer was $\geq 3 \log_{10}$ after a 5-minute exposure to Microcyn Technology.¹¹

Sporicidal activity. Microcyn Technology was tested to determine sporicidal characteristics against spores of *Bacillus atrophaeus* (ATCC #6633). The test was conducted in accordance with the BS En 14347:2002 "draft" standard. After 15 minutes of exposure, the reduction in spores was $6.5 \log_{10}$ on average, thus completing the requirements of the applied test method (MicroMed Laboratories, Petaluma, Calif.).

Toxicology Studies

Safety has also been a major issue in formulating Microcyn Technology. A series of testings have been conducted to show that the use of Microcyn Technology does not cause toxicity, irritation, or sensitivity (Table 1). All of these tests have been conducted according to FDA standards or

International Organization for Standardization (ISO) standards at GLP facilities.

A major concern when using super-oxidized solutions is the potential induction of genotoxicity. In accordance, a micronucleus testing conducted as per ISO standards has shown that Microcyn Technology is not genotoxic.

The effects of Microcyn Technology on fibroblast viability and wound healing have also been addressed in 2 unpublished, third-party lab studies at North American Science Associates, Inc. (NAMSA), Northwood, Ohio, and Comparative Biosciences, Inc., Sunnyvale, Calif., in 2004. In the first study, the cytotoxicity test on fibroblasts was executed in accordance with ISO 10993-5:1999 standards. A filter disc with 0.1 mL of Microcyn Technology was placed onto an agarose surface, directly overlaying a monolayer of mouse fibroblast cells (L-292). The prepared samples were observed for cytotoxic damage after 24 hours. Under these conditions, Microcyn Technology-containing samples did not reveal any evidence of cell lysis or toxicity (NAMSA).

The second study was conducted with 16 rats to evaluate the local tolerability of Microcyn Technology and its effects on the histopathology of wound beds in a model of full-thickness dermal wound healing. It had already been shown that neutral pH super-oxidized solutions were not only non-toxic to wounds, but that they could even induce wound healing.¹³ In this study, Masson's trichrome-stained sections and collagen type II-stained sections of the Microcyn Technology and saline-treated surgical wound sites were evaluated by a board-certified veterinary pathologist. As expected, there were no relevant histopathologic differences between the treatment groups, indicating that the Microcyn Technology treatment was well-tolerated. There were no significant differences between groups in collagen type II expression. As expected, Microcyn Technology did not have an adverse effect on fibroblasts or on collagen elaboration under the conditions of this study (Comparative Biosciences).

Worldwide Approvals

In 2004, a European approval was obtained (CE KEMA - Medical Device Class IIb). Dermacyn Wound Care (formulated with Microcyn Technology) is a super-oxidized solution intended for use in the moistening, irrigation, debridement, and microbial load reduction of acute and chronic wounds, ulcers, cuts, abrasions, and burns. In the United States, 2 510(k)s from the FDA were approved in May 2005:

1. Dermacyn™ Wound Dressing is indicated for use in moistening and lubricating absorbent wound dressings for traumatic wounds, cuts, abrasions, and minor burns

2. Dermacyn Wound Care is intended for cleansing, debriding, and removing foreign material from acute and chronic dermal lesions such as stage IV pressure ulcers, diabetic ulcers, post-surgical wounds, first- and second-degree burns, abrasions, and minor irritations of the skin.

Clinical Studies

Microcyn Technology has been effective and safe when applied in different ways (eg, spray, immersion, irrigation), as well as in combination with other technologies such as vacuum-assisted closure (VAC Therapy, KCI, San Antonio, Texas) and the Versajet Hydrosurgery system (Smith & Nephew, Largo, Fla.). According to the type and stage of the lesion, it can be applied once, twice, or 3 times daily.

Pilot clinical evaluations—mainly in Latin America and Europe—have already been conducted by independent

Microcyn® Technology has been effective and safe when applied in different ways (eg, spray, immersion, irrigation), as well as in combination with other technologies.

physicians to test for efficacy and safety in diabetic foot and venous stasis ulcers, burns, and postoperative wounds. Good results have been reported in these cases. For example, one study has shown better results with Dermacyn Wound Care over povidone iodine in the treatment of 208 patients with diabetic foot ulcers in Italy.⁵

Oculus is also currently involved in the planning and execution of numerous clinical studies and post-approval human-use evaluations throughout the United States, Mexico, and Europe.

Conclusion

The use of super-oxidized solutions as wound care products is a cutting-edge concept. The first stable and commercially available super-oxidized solution, Dermacyn Wound Care (Europe) and Oculus Microcyn60 (Mexico), has been shown to be an efficient antimicrobial agent in *in-vitro* experiments. The moistening effect and the minimum toxicity found with the

use of this super-oxidized solution makes it a good choice for wound care management. However, new controlled trials must be conducted to fully characterize the antimicrobial, anti-inflammatory, and positive effects in wound healing. Nevertheless, preliminary results suggest that this non-antibiotic technology appears to offer a broad new paradigm for the prevention and treatment of acute and chronic wounds.⁵ The potential application of this technology warrants further research, and specialized formulations are now being developed for various indications. ■

11. Landa-Solis, González-Espinosa D, Guzman B, et al. Microcyn a novel super-oxidized water with neutral pH and disinfectant activity. *J Hosp Infect.* (2005;61(4):291–299.
12. Federal Register. Tentative Final Monograph. 17 June 1994, vol. 59:116,p.31444.
13. Yahagi N, Kono M, Kitahara M, et al. Effect of electrolyzed water on wound healing. *Artif Organs.* 2000;24(12)984–987.

References

1. Park H, Hung YC, Kim C. Effectiveness of electrolyzed water as a sanitizer for treating different surfaces. *J Food Prot.* 2002;65(8):1276–1280.
2. Rutala WA, Weber DJ. New disinfection and sterilization methods. *Emerg Infect Dis.* 2001;7(2):348–353.
3. Tanaka N, Tanaka N, Fujisawa T, et al. The use of electrolyzed solutions for the cleaning and disinfecting of dialyzers. *Artif Organs.* 2000;24(12):921–928.
4. Nelson D. Newer technologies for endoscop disinfection: electrolyzed acid water and disposable-component endoscope systems. *Gastrointest Endosc Clin N Am.* 2000;10:319–328.
5. Dalla Paola L, Brocco E, Senesi A, et al. Use of Dermacyn, a new antiseptic agent for the local treatment of diabetic foot ulcers. *Journal of Wound Healing.* 2005;2:201.
6. Sekiya S, Ohmori K, Harii K. Treatment of infectious skin defects or ulcers with electrolyzed strong acid aqueous solution. *Artif Organs.* 1997;21(1):32–38.
7. Ohno H, Higashidate M, Yokosuka T. Mediastinal irrigation with superoxidized water after open-heart surgery: the safety and pitfalls of cardiovascular surgical application. *Surg Today.* 2000;30(11):1055–1056.
8. Inoue Y, Endo S, Kondo K, et al. Trial of electrolyzed strong acid aqueous solution lavage in the treatment of peritonitis and intraperitoneal abscess. *Artif Organs.* 1997;21(1):28–31.
9. Sakashita M, Iwasawa A, Nakamura Y. Antimicrobial effects and efficacy on habitually hand-washing of strong acidic electrolyzed water—a comparative study of alcoholic antiseptics and soap and tap water. *Kansenshogaku Zasshi.* 2002;76(5):373–377.
10. Martinez-Munive A, Menedez-Skertchly A, Toiber M, et al. Super-oxidized water (Microcyn 60) for mesh hernioplasty in grossly contaminated fields: an experimental study. SE 163. Presented at the American College of Surgeons 91st Annual Clinical Congress in San Francisco, California, October 16–20, 2005.



Advanced Wound Care with Stable, Super-Oxidized Water

A look at how combination therapy can optimize wound healing

Tom A. Wolvos, MD, FACS

The author became interested in a new, super-oxidized water after reading an article in *Forbes* magazine.¹ Microcyn® Technology, now available in the United States under the brand of Dermacyn Wound Care (Oculus Innovative Sciences, Petaluma, Calif), is a super-oxidized, non-toxic, non-irritating, no rinse, dermal wound irrigant. The author published the first US article on the VAC Instill System (KCI, San Antonio, Tex), a system that combines negative pressure wound therapy with the controlled, intermittent delivery of topical wound solutions and suspensions over the wound bed,² and had been searching for an ideal solution to use with the System. Thus, a study was conducted to determine the clinical results of using Dermacyn not only with the VAC Instill System, but also in treating a variety of patients in an advanced wound care practice. This article will review the results of this study and discuss wound irrigation.

Study Results

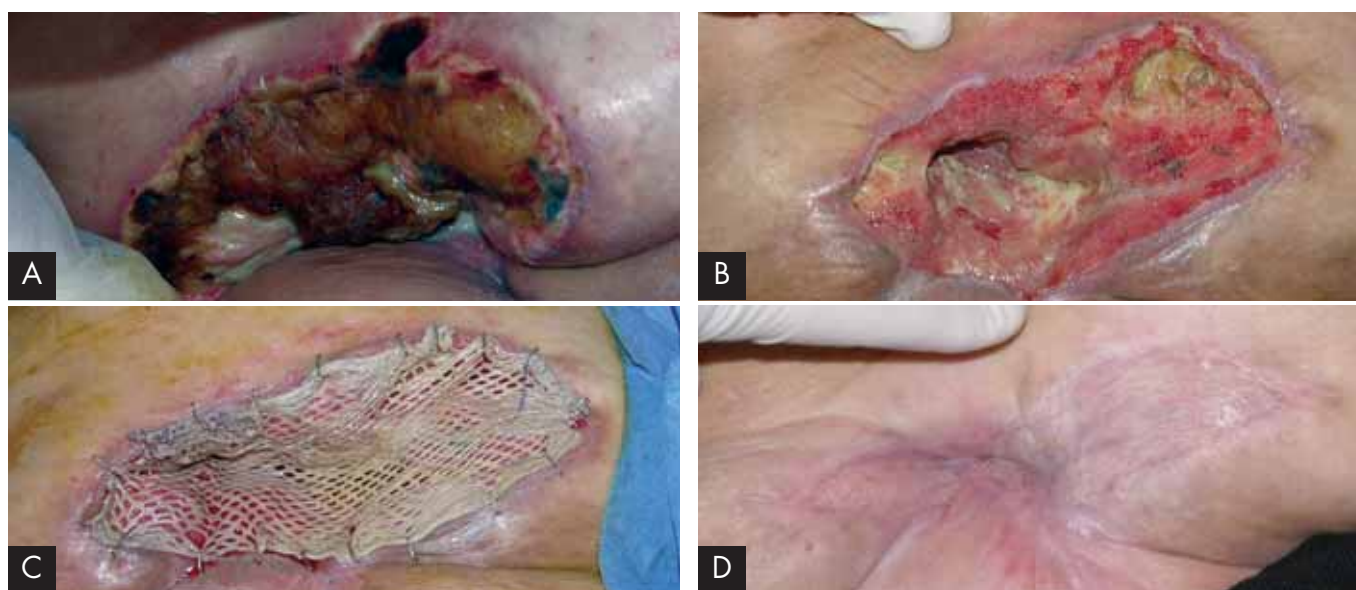
The author began using Dermacyn in June 2005 to treat 26 patients with 30 various wound types, which fall into the following categories:

- Postoperative wounds (9 patients): perforated appendix; open abdominal wound after surgery for a perforated colon; open abdominal wound after closure of a jejunostomy; skin graft wounds; below-the-knee amputation incision line wounds; abdominal wall wound post application of bilayered cell therapy (Apligraf, Organogenesis Inc., Canton, Mass); saphenous vein donor site wound; and groin wound
- Traumatic wounds (3 patients): dog bite; abrasion contusions of the leg; and lacerations of the leg
- Decubitus ulcers (2 patients)

- Diabetic foot wounds (5 patients)
- Dehisced abdominal wall wounds with exposed abdominal wall mesh (5 patients)
- Patients with Integra (Integra Lifesciences Corporation, Plainsboro, NJ) placed in their wounds (2 patients).

Postoperative wounds. One wound from this category was a groin wound in a 61-year-old woman who underwent coronary bypass grafting. The patient had an invasive line and bled into her groin and, consequently, had surgery to address the problem. She became septic in a nursing facility and was transferred to the author's hospital. Figure 1A shows her wound on admission (right groin crease, lower abdominal wall and right leg). She was started on traditional VAC Therapy (KCI) and was subsequently switched to the VAC Instill System. The wound improved (Figure 1B) and was skin grafted (Figure 1C). Vacuum-assisted closure therapy was used to bolster the split-thickness skin graft. Postoperatively, the patient healed most of her wound except for an area in the center. She was started on Dermacyn dressing changes twice a day. The wound was irrigated with full-strength Dermacyn and then twice daily, a gauze moistened with Dermacyn was placed in the wound. This patient's wound progressed to complete healing (Figure 1D).

Traumatic wounds. Dermacyn appears to have a role in the wound-healing continuum. A 77-year-old woman with diabetes presented with a traumatic wound of the right lower leg (Figure 2A). Eschar over the wound was completely excised, and the wound was treated daily with the enzymatic debrider Accuzyme (Healthpoint, Ltd., Fort Worth, Tex). After 2 weeks, the patient was experiencing some burning, and the area around the wound was red. Her wound care was switched to Dermacyn dressing changes. Figure 2B shows the wound after



Figures 1A–D: Patient’s wound at presentation (A), after VAC Instill therapy, (B), after placement of split-thickness graft (C), and the wound once it healed (D).

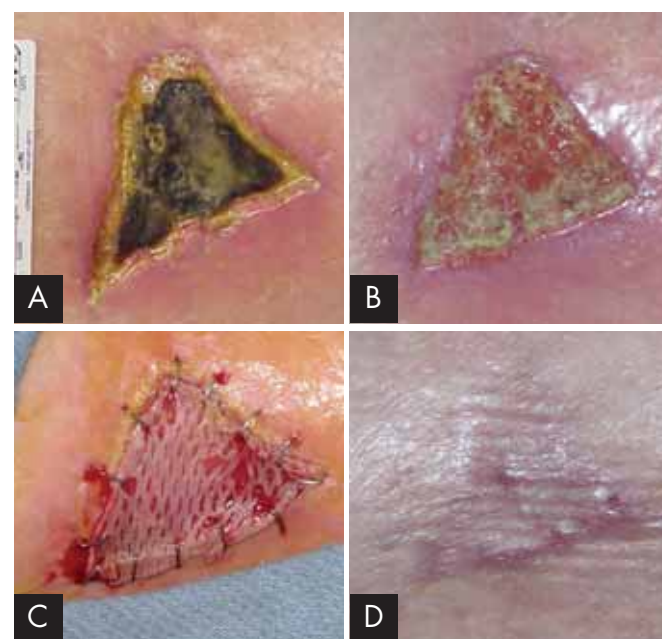
using Dermacyn for 2 weeks. Vacuum-assisted closure was started pre-op in preparation for a skin graft. Figure 2C shows the operative picture of the split-thickness skin graft. The patient was discharged the day of her skin graft surgery using VAC Therapy to bolster the graft. Figure 2D shows the healed wound at a post-op visit.

Decubitus ulcers. Dermacyn appears to have a role as the topical agent for wound irrigations and to moisten dressings in patients with decubitus ulcers. It should be considered for treating a decubitus ulcer that is too large for an enzymatic agent but too small for VAC Therapy.

Diabetic foot ulcers. A 59-year-old man with a diabetic foot wound was treated with the VAC Instill System using Dermacyn as the irrigation solution. In addition, the patient received hyperbaric oxygen treatments, surgical debridement, and bilayered cell therapy. Figure 3A shows this patient’s wound before treatment. Figure 3B shows the wound with the VAC Instill dressing in place (at this time, he was receiving intermittent, full-strength Dermacyn irrigations with the VAC Instill System), and Figure 3C shows the contracted wound completely covered with healthy granulation tissue.

Exposed abdominal wall mesh. The VAC Instill was used with Dermacyn as the irrigation solution in a series of patients who had dehiscenced abdominal wounds with exposed AlloDerm mesh (LifeCell Corporation, Branchburg, NJ) and Permacol surgical implant (Tissue Science Laboratories, PLC, Aldershot, Hampshire, UK). These wounds became covered with healthy granulation tissue and were able to be skin grafted, which led to complete healing.

Patients with Integra placed in their wounds. Integra Bilayer Matrix Wound Dressing acts as a dermal matrix to help form the dermal layer of skin. It can become ineffective if it becomes infected. In 2 patients, the author soaked Integra in Dermacyn in the operating room prior to placement on the patient. Soaking Integra in Dermacyn may decrease the incidence of infection of Integra in the post-op period.



Figures 2A–2D: Leg wound at presentation (A), 2 weeks after Dermacyn use (B), after skin graft (C), and once it completely healed (D).

The Concept of Wound Irrigation

The goal of wound irrigation is to remove debris and bacteria from the wound while minimizing injury to the normal tissue around the wound. At dressing changes, it is tempting to remove the old dressing and apply a new dressing without dealing with the wound itself. Wound irrigation can help improve wound healing. The delivery pressure of wound irrigation appears to play an important factor in promoting wound healing. A delivery pressure of 5–10 psi has been an accepted range for removing debris and bacteria from a wound while minimizing the damage to the surrounding normal tissues.³

It is common to see fluid from a bottle being poured directly into a wound or to see a bulb syringe or an asepto syringe used to irrigate a wound at dressing changes. Virtually no pressure (0–1 psi) is delivered to a wound when a pour-bottle technique or bulb or asepto syringe is used. On the other hand, a 35-cc piston syringe with a 19-gauge needle delivers a psi of about 8.⁴ When comparing gross infection, induration, and bacterial counts with a low-pressure asepto syringe versus the higher pressure achieved with a 35-cc syringe and 19-gauge needle, the results showed that there is a clinical advantage of using the higher pressure system (35-cc syringe/19-gauge needle).⁴ Some studies suggest that an antiseptic solution is more effective than just saline alone when used as a wound cleanser to promote wound healing.⁵

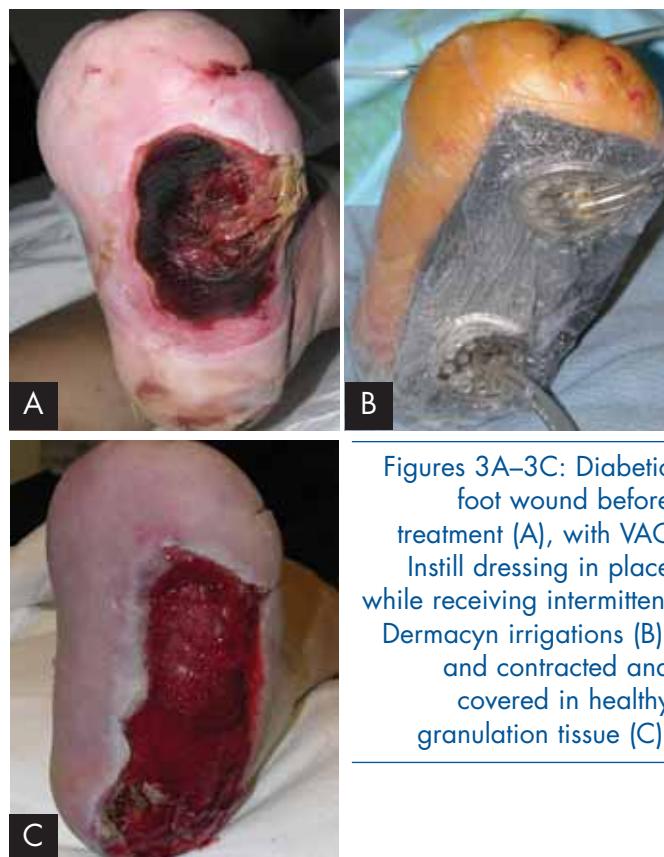Discussion

There have been no reported cases of toxicity or side effects with Dermacyn. Dermacyn appears to only attack single-celled organisms while sparing multicellular organisms.

In this series of patients, Dermacyn appears to be an effective solution for moistening and debriding wounds. In the past, super-oxidized waters have been shown to have antiseptic properties.⁶ In the patients studied in this series, Dermacyn also appears to be an effective wound antiseptic.

Dermacyn can be used to treat a variety of wounds from simple to extremely complex. It can be used as the wound irrigation solution at simple dressing changes, and it can serve as the solution with which to moisten the gauze used to dress the wound.

Dermacyn is complimentary to a wide variety of advanced wound-healing products and methods. For example, it can be used as an irrigant at traditional VAC Therapy dressing changes and as the irrigation solution with the VAC Instill. It can also be used for pressurized wound irrigation either with a simple system (a 35-cc syringe and a 19-gauge needle) or with more formal wound irrigation products, such as the Versajet Hydrosurgery system (Smith & Nephew, Largo, Fla) or jet lavage wound cleansing and debridement system (JetOx-ND, DeRoyal, Powell, Tenn).



Figures 3A–3C: Diabetic foot wound before treatment (A), with VAC Instill dressing in place while receiving intermittent Dermacyn irrigations (B), and contracted and covered in healthy granulation tissue (C).

Dermacyn also appears to be safe to use with tissue-engineered products and dermal substitutes. Further clinical studies will help confirm the effectiveness and compatibility of Dermacyn in the field of advanced wound care. ■

This study was supported by an unrestricted research grant by Oculus Innovative Sciences.

References

1. Egan ME. Holy Water. *Forbes*. February 28, 2005.
2. Wolvos T. Wound instillation — the next step in negative pressure wound therapy. Lessons learned from initial experiences. *Ostomy Wound Manage*. 2004;50(11):56–66.
3. Luedtke-Hoffmann KA, Schafer DS. Pulsed lavage in wound cleansing. *Phys Ther*. 2000;80(3):292–300.
4. Stevenson TR, Thacker JG, Rodeheaver GT, et al. Cleansing the traumatic wound by high pressure syringe irrigation. *JACEP*. 1976;5(1):17–21.
5. Lindfors J. A comparison of an antimicrobial wound cleanser to normal saline in reduction of bioburden and its effect on wound healing. *Ostomy Wound Manage*. 2004;50(8):28–41.
6. Tanaka H, Hirakata Y, Kaku M, et al. Antimicrobial activity of super-oxidized water. *J Hosp Infect*. 1996;34(1):43–49.



Treating Diabetic Foot Ulcers with Super-Oxidized Water

A look at advances in this pH-neutral, non-toxic treatment

Luca Dalla Paola, MD

Infection is one of the most important factors in determining the risk of amputation in patients with diabetes.¹⁻¹¹ If a standardized treatment is applied with a multidisciplinary foot care team, major amputation can be avoided in about 80–90% of patients with limb-threatening ischemia and in 95% of patients with infection.^{7-10,12-15} Surgical treatment is a useful tool for treating infection in diabetic feet.^{7-10,12,13,15-17}

Antiseptics can be used to prevent and treat infection and to preserve the healing process. They are preferable to topical antibiotics with regard to the development of bacterial resist-

If a standardized treatment is applied with a multidisciplinary foot care team, major amputation can be avoided in about 80–90% of patients with limb-threatening ischemia and in 95% of patients with infection.^{7-10, 12-15}

ance.¹⁸ Some experts argue against the use of antiseptic agents in wound treatment, and the major reason behind these arguments is the cytotoxicity against the host's dermal and epidermal cells. There is poor evidence of using local antiseptic agents in infected feet.¹⁸ Despite the weak evidence, antiseptics are used in clinical practice for infected skin and

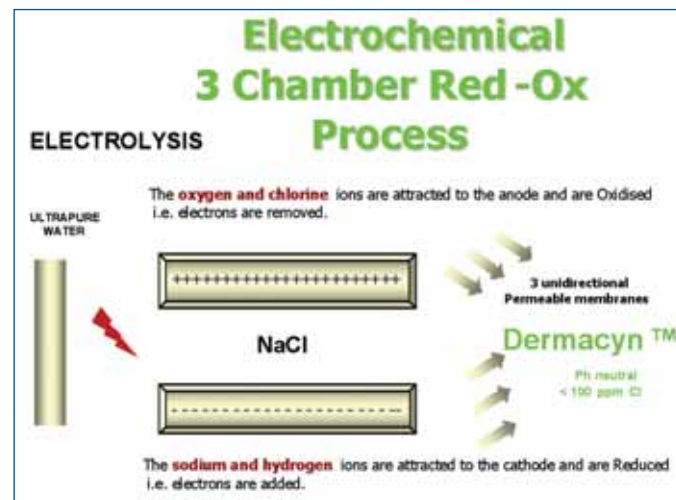


Figure 1: The production process of Dermacyn.

wounds.^{2,18-20} There is concern about the effect of antiseptics on diabetic foot ulcers. This is where super-oxidized solutions, such as Dermacyn Wound Care (formulated with Microcyn® Technology, Oculus Innovative Sciences, Petaluma, Calif) play a role. This article will review the use of Dermacyn Wound Care in the treatment of diabetic foot ulcers.

Examples of Dermacyn in Action

Figure 1 shows the production process of Dermacyn. This super-oxidized solution is used in both emergent and elective surgery when surgical and physical debridement is performed with pulsated irrigation, ultrasound debriders, and vacuum-assisted closure therapy (VAC Therapy, KCI, San Antonio, Tex.). It is used when clinical impression suggests the presence of infection and can be utilized with skin grafting and bioengineered tissue.

Figure 2 shows a patient who presented with gangrene and plantar necrosis and required emergent surgery to treat both the gangrene and plantar compartment syndrome. Dermacyn was applied to the wound daily for 90 days until it healed.

The VAC Instill System is not yet available in Italy, so Dermacyn is injected daily over the foam with the VAC Therapy. Physicians in Italy are also using Dermacyn before skin grafts in open amputations, as shown in Figure 3.

Dermacyn Data

Between November 2004 and March 2005, 218 patients with diabetes were enrolled in a randomized, single-center, Italian study that evaluated the effectiveness of Dermacyn. Stage II and III ulcers were enrolled using Texas University Classification of foot ulcers, and 110 of the enrolled patients were randomized to the Dermacyn group and 108 to the control group. The 2 groups were matched for age, duration of diabetes, and class of ulceration.

All patients with peripheral vascular disease (PVD) were referred for revascularization using endovascular techniques or bypass surgery.^{6,21-24} Surgical treatment of bone infection (esotectomy or minor amputations) was performed in patients with osteomyelitis and a microbiological specimen was taken every month from the time of enrollment and randomization until closure to evaluate the number and quality of bacterial strains.

Local treatment was carried out daily using gauze soaked with Dermacyn (in the Dermacyn group) or povidone iodine (in the control group). Elective surgery was carried out after clinical improvement of infection and revascularization. Differences between the groups in favor of Dermacyn were apparent in the reduction of the number of bacterial strains, local adverse effects, surgical dehiscence, amputation rates and healing time. The study has already been submitted for publication.

Conclusion

Infection is a negative prognostic factor that explains the high risk of amputation in patients with diabetes and foot ulcers. Aggressive treatment (antibiotic treatment combined with surgery) allows us to reach a high percentage of limb salvage. Treatment of infection requires aggressive local debridement of nonviable, soft tissues and treatment of osteomyelitis.

No strong evidence shows efficacy of local antiseptic agents in the treatment of diabetic foot infection. Despite this lack of evidence, clinicians use antiseptic agents as ancillary treatment in infected feet.

The results of this study therefore appear to show more favorable results for Dermacyn than for povidone iodine. However, although the results are highly statistically significant, the

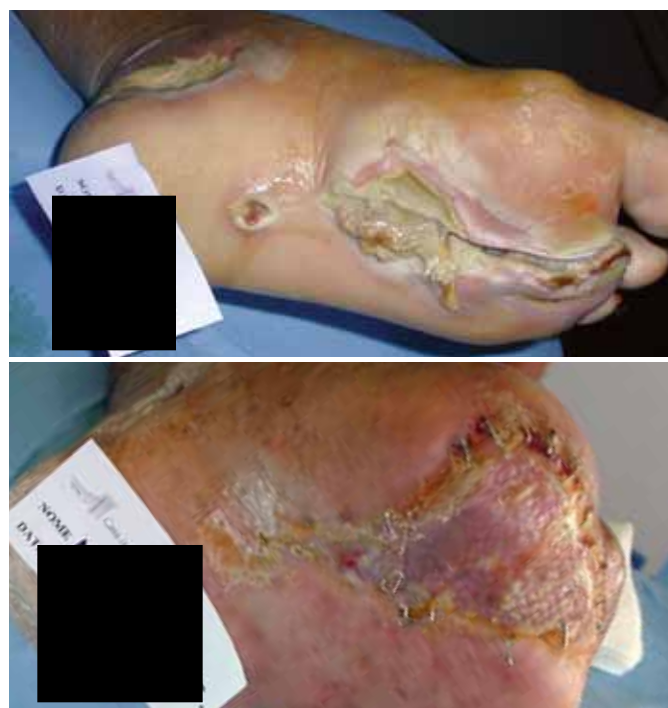

Figure 2: The top photo shows the foot of a patient with gangrene and plantar necrosis, while the bottom photo shows the wound once it healed.

strength of evidence for the superiority of Dermacyn over povidone iodine depends on the study design. The results of this study justify further research into the use of Dermacyn in the treatment of diabetic ulcers. It is important to ensure that possible sources of bias in future studies are excluded, for example, by randomization of patients to treatment and by blinded assessment of outcomes. ■

References

1. Adler EI, Boyko EJ, Ahroni JH, et al. Lower extremity amputation in diabetes: the independent effects of peripheral vascular disease, sensory neuropathy, and foot ulcers. *Diabetes Care*. 1999;22(7):1029-1035.
2. American Diabetes Association. Presented at the Consensus Development Conference on Diabetic Food Wound Care in Boston, Massachusetts, April 7-8, 1999. *Diabetes Care*. 1999;22(8):1354-1360.
3. Boiko EJ, Lipsky BA. Infection and diabetes mellitus. In: Harris MI (ed): *Diabetes in America*, Second Edition. Diabetes data compiled 1995. Bethesda, MD: National Institutes of Health. NIH publication No: 95-1468, 1995, pp485-499.

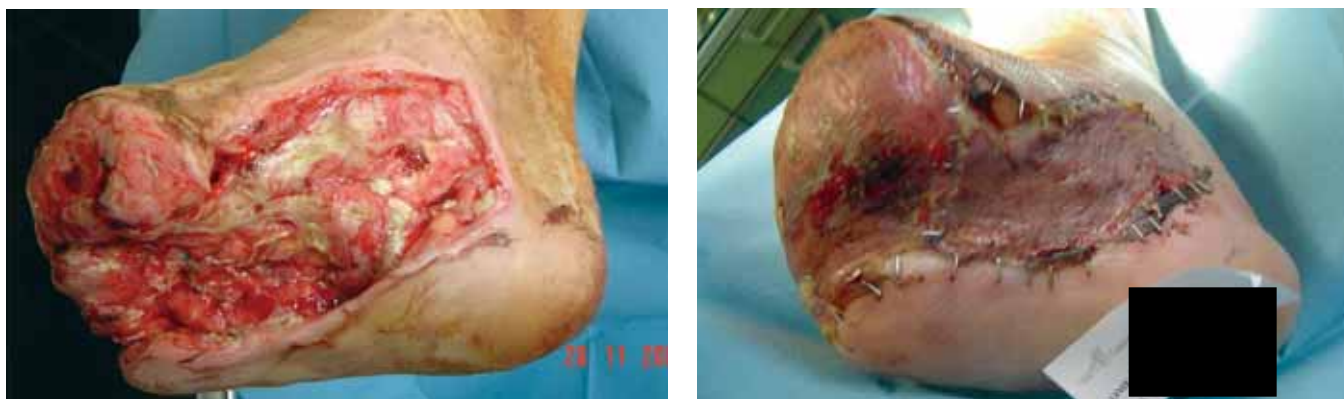

Figure 3: An example of Dermacyn used in an open amputation (as shown in the figure on the left) and before the placement of a skin graft, such as the one pictured at right.

4. Chang BB, Darling RC III, Paty PSK, et al. Expedient management of ischemic invasive foot infections. *Cardiovasc Surg*. 1996;4(6):792-795.
5. Chantelau E, Tanudjaja T, Altenhofer F, et al. Antibiotic treatment for uncomplicated neuropathic forefoot ulcers in diabetes: a controlled trial. *Diabet Med*. 1996;13(2):156-159.
6. Eneroth M, et al. Clinical characteristic and outcome in 223 diabetic patients with deep foot infections. *Foot Ankle Int*. 1997;18(11):716-722.
7. Gibbons GW. The diabetic foot: amputations and drainage of infection. *J Vasc Surg*. 1987;6(5):791-793.
8. Grayson ML, Gibbons GW, Balogh K, et al. Probing to bone in infected pedal ulcers: a clinical sign of underlying osteomyelitis in diabetic patients. *JAMA*. 1995;273(9):721-723.
9. Holstein P, Sorenson S. Limb salvage experience in a multidisciplinary diabetic foot unit. *Diabetes Care*. 1999;22(Suppl 2).
10. Lipsky BA. Infectious problems of the foot in diabetic patients. In: Bowker JH, Pfeifer MA (eds). Levin and O'Neal's The Diabetic Foot. Sixth Edition. Mosby, 2001.
11. Ramsey SD, Newton K, Blough D, et al. Incidence, outcomes, and cost of foot ulcers in patients with diabetes. *Diabetes Care*. 1999;22(3):382-387.
12. Armstrong DG, Frykberg RG. Classifying diabetic foot surgery: toward a rational definition. *Diabet Med*. 2003;20(4):329-331.
13. Holstein P, Ellitsgaard N, Olsen BB, Ellitsgaard V. Decreasing incidence of major amputations in people with diabetes. *Diabetologia*. 2000;43(7):844-847.
14. Larsson J, Apelqvist J, Agardh CD, Stenstrom A. Decreasing incidence of major amputations in diabetic patients: a consequence of a multidisciplinary foot care team approach? *Diabet Med*. 1995;12(9):770-776.
15. Rosenblum BI, Pomposelli FB, Giurini JM, et al. Maximizing foot salvage by a combined approach to foot ischemia and neuropathic ulceration in patients with diabetes. A 5-year experience. *Diabetes Care*. 1994;17(9):983-987.
16. Caputo GM, Cavanagh PR, Ulbrecht JS, et al. Assessment and management of foot disease in patients with diabetes. *N Engl J Med*. 1994;331(13):854-860.
17. Cavanagh PR, Buse JB, Frykberg RG, et al. For the American Diabetes Association: diabetic foot wound care. Presented at the Census Development Conference held in Boston, Massachusetts, April 7-8, 1999. *Diabetes Care*. 1999;22(8):1354-1360.
18. Drosou A, Falabella A, Kirsner S. Antiseptics on wounds: an area of controversy. *WOUNDS*. 2003;15(5):149-166.
19. Bergstrom N, Bennet MA, Carlson CE, et al. Clinical practice guideline number 15: treatment of pressure ulcers. Rockville MD: US Department of Health and Human Services. Agency for Health Care Policy and Research. AHCPR Publication. 1994;65-0652.
20. International Consensus on the diabetic foot. Amsterdam: International Working Group on the Diabetic Foot, 1999.
21. Edmonds M, Forster AVM. Reduction of major amputations in the diabetic strategy to "take control" with conservative care as well as revascularization. *VASA* 2001;58(suppl):6-14.
22. Faglia E, Dalla Paola L, et al. Peripheral angioplasty as the first choice revascularization procedure in diabetic patients with critical limb ischemia: prospective study of 993 consecutive patients hospitalized and followed between 1999 and 2003. *Eur J Vasc Endovasc Surg*. 2005;29(6):620-627.
23. Faglia E, Favales F, Aldeghi A, et al. Change in major amputation rate in a center dedicated to diabetic foot care during the 1980s: prognostic determinants for major amputation. *J Diabetes Complications*. 1998;12(2):96-102.
24. Faglia E, Mantero M, Caminiti M, et al. Extensive use of peripheral angioplasty, particularly infrapopliteal, in the treatment of ischemic diabetic foot ulcers: clinical results of a multicentric study of 221 consecutive subjects. *J Intern Med*. 2002;252(3):225-232.



Reducing Bacterial Infectious Complications from Burn Wounds

A look at the use of Oculus Microcyn60 to treat wounds in Mexico

Ariel Miranda Altamirano, MD

Burns are a major problem associated with high morbidity in Mexico. In 2003, 20,330 burn cases were reported, mostly in children.¹ Despite improvements in multidisciplinary treatment, infection remains the leading cause of death among patients who are hospitalized.

Burn wound infections account for 3–7% of all infections in patients with burns in the United States.² These occur most frequently in children, followed by elderly patients. The incidence of burn infection can reach >10% for a rate of 5.6/1,000 patient-days in certain specialized burn units in the United States.³ However, these rates are much higher in other countries, such as Mexico, because of overcrowded facilities, fewer infection control barriers, and less access to immediate wound debridement or antimicrobial therapies (compared to the United States).

Burn Etiology and Other Facts

The risk of burn wound infection is directly correlated to the extent of the burn and is related to impaired resistance resulting from disruption of the skin's mechanical integrity and generalized immune suppression. Infections in burn wounds may be classified as wound cellulitis (ie, unburned skin at the margin of the burn) or as an invasive wound infection (ie, microbial invasion of viable tissue beneath the burn wound eschar). Bacterial burn wound infections are most commonly caused by *Staphylococcus aureus*, *Pseudomonas aeruginosa*, *Enterobacter cloacae*, *Klebsiella pneumoniae*, *Enterococcus faecalis*, and *Acinetobacter baumannii*.

Advances in local burn therapies, including the judicious use of antimicrobials, undoubtedly have reduced bacterial infectious complications from burns. Unfortunately, the number of opportunistic infections in burn wounds has risen significantly.

Thus, infections with antibiotic-resistant bacteria (eg, methicillin-resistant *S. aureus*) and fungal pathogens (eg, *Aspergillus*, *Candida*, and *Mucor* species) have been steadily increasing in recent years. These kinds of infections are mostly seen in patients sustaining larger burns (>40% total body surface area [TBSA]) who receive multiple doses of broad-spectrum perioperative antibiotics.

Overall, mortality rates from burn wound sepsis remain high. However, independent of the thickness of the wound, the presence of infection could also severely retard the wound healing process, increase the rates of graft loss, deteriorate the cosmetic results, and elevate hospital expenses.^{4,5} Therefore, the management of the wound should focus on avoiding infection and preventing the progression of the injury from day 1.

Management of Burns

The management of severe burn wounds is multidisciplinary. Permeable airways, volume repletion, and early removal of necrotic tissue followed by wound closure are the key goals. Effective topical antimicrobial therapy and daily wound inspection are necessary to monitor for infection, which may cause conversion of partial-thickness burns to full-thickness injuries.

It is remarkable that the anti-infective topical treatment of wounds has not significantly changed in the past 50 years. The standard care may vary among institutions, but it usually starts with cleansing of the wounds with saline solution and a surgical detergent (eg, chlorhexidine gluconate), followed by the application of silver sulfadiazine or mafenide acetate burn creams. (Dakin's solution and betadine are alternative agents already in disuse.) Burns are then treated while either open or closed. With the use of this approach, the infection rates were kept in the range of 3–7% in patients treated in the United

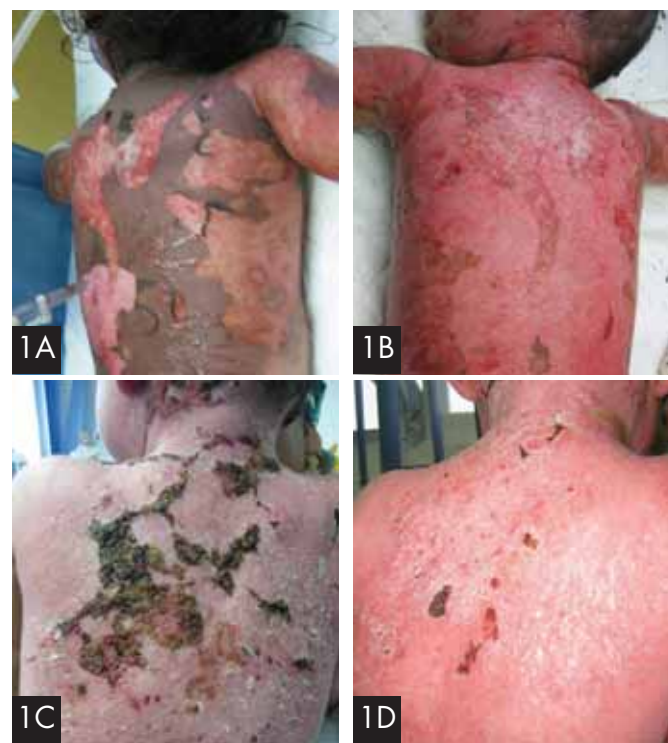States, but the infections rates are higher in poorer countries.²

The major drawbacks of all antiseptics, however, have been the narrow antimicrobial spectrum and their known cytotoxicity to the burn area, skin grafts, and dermal substitutes. The opaque quality of betadine precludes the early detection of underlying infection in the wound bed. Silver sulfadiazine and cadexomer iodine require long exposure times to kill a wide range of bacteria and viruses. Additionally, these solutions cannot be used on certain parts of the body, such as around the eyes, and patients sometimes have negative reactions to these products due to their toxicity. Furthermore, silver-based products require exact dosage and close monitoring by trained medical staff to minimize the potential for mutations and bacterial resistance. Several other topical antibiotics and silver-containing dressings have also been used, but they are expensive and not widely available in poorer countries. The emergence of multi-drug-resistant bacteria and fungal infections is yet another important problem to consider if the topical antimicrobial fails.

As an alternative, super-oxidized solution has been used for disinfecting burn wounds and for preventing *Pseudomonas* sepsis in a rat model.⁶ The literature also describes the effectiveness of super-oxidized solutions for the treatment of infectious skin defects or ulcers in humans.⁷ Late in 2003, a novel super-oxidized solution (Oculus Microcyn60™) was introduced in Mexico as a wound care product. It is a stable, pH-neutral, bactericidal, fungicidal, virucidal, and sporocidal solution.⁸ It was shown that this solution was not an irritant, nor was it sensitizing, according to international standards for wound care products (Oculus Innovative Sciences; Stillmeadow, Inc., Sugar Land, Texas, 2004, unpublished data). Oculus Microcyn60 did not alter the normal healing process.⁹ Clinical studies with Oculus Microcyn60 also show a favorable outcome in diabetic leg ulcers and chronic venous stasis ulcers (see Dr. Dalla Paola's study on page 14 of this supplement).¹⁰ Because silver-based solutions have not been available in Mexico since 2004, and no side effects have been reported with Oculus Microcyn60, the latter has become the standard topical antimicrobial treatment for partial- and full-thickness burns in pediatric patients at the burn unit of Hospital Civil de Guadalajara in Mexico.

Clinical Cases

In total, 64 children admitted to the Hospital Civil de Guadalajara in Mexico from March 2004 to March 2005 with a diagnosis of superficial-partial, deep-partial, and full-thickness thermal injuries to the skin have entered the study. Retrospective analysis of paired cases presenting similar burns at that institution during 2003 was undertaken for the control group. The objective of the present study was to evaluate the



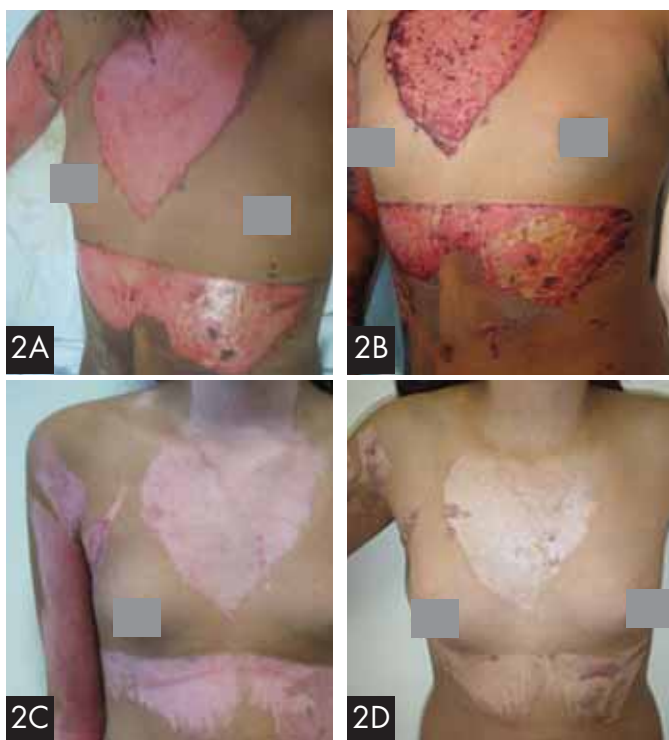Figures 1A–1D. A 2-year-old girl with partial-thickness burns.

use of Oculus Microcyn60 in burns by its actions in infection control, healing activity, hospital length of stay, antibiotic use, and final scar evaluation.

In all cases, surgical and/or high-pressure debridement with the JetOx™ system (De Royal, Powell, Tenn.) was conducted under general anesthesia at entry. Partial-thickness burns were left open without gels or dressings. Full-thickness burns with abundant exudate were debrided and covered with dressings. Skin grafts were also used as necessary. Samples for microbial cultures were taken before the excision and at different points in the first 2 weeks. After the initial debridement, the burn wounds were moistened with Oculus Microcyn60 3 times each day using a spray trigger. The final results of this clinical evaluation are now under review for publication. Following are details from 2 of the 64 cases.

Case 1

A 2-year-old girl presented with 33% TBSA partial-thickness burns after exposure to boiling water (Figure 1A). She underwent debridement with the JetOx system and, as in the rest of the cases, the lesion was moistened with Oculus Microcyn60 3 times each day using a spray trigger. The children tolerated the daily cleaning of the lesion without much pain. At day 3, the typical bright red color in the burn area was present (Figure 1B). Aseptic eschars then appeared on weeks 1 and 2 and were not removed (Figure 1C). Re-epithelization of the wounds usually occurred in weeks 3–4 (Figure 1D). At follow up, the characteristics of the new skin were similar to the spared skin, albeit a different color.



Figures 2A–2D. A 12-year-old girl with partial- and full-thickness burns.

Case 2

A 12-year-old girl presented with 43.5% TBSA partial- and full-thickness burns after her clothes were ignited with electrical discharge (Figure 2A). Granulation tissue with aseptic scar formation appeared in all lesions at day 5 (Figure 2B). On day 21, there was complete epithelization in the neck, axilla (Figure 2C), and leg without deforming scars or the use of skin grafts in the leg. Note the excellent cosmetic results after 1 year of treatment (Figure 2D).

Comments and Perspectives

Currently, wide variation exists in the topical treatment for burn patients. The goal remains to identify the most cost-effective measures to prevent outbreaks of infection involving other patients in the unit.

Sulfadiazine is the most commonly used topical anti-infective on burn patients worldwide because it is useful in prevention of infections from second- or third-degree burns. It has bactericidal activity against many Gram-positive and Gram-negative bacteria and a mild antifungal activity. Unfortunately, it is not available in Mexico.

As predicted from previous animal and clinical experience, the use of Oculus Microcyn60 was efficient and safe for the prevention of partial- and full-thickness burn infections in pediatric patients. Treatment with Oculus Microcyn60 reduced the microbial load in 90% of patients with partial- and full-thickness

thermal injuries. Children also reported less pain during cleaning procedures. Application was easy and inexpensive. In addition, the length of hospital stay of patients treated with Oculus Microcyn60 was reduced by 50% relative to the control. Considering that the daily hospital cost at this facility is approximately \$1,800 US per patient, treatment with Oculus Microcyn60 saved the institution an average of \$24,660 US per patient. The results of this study also suggest that burns treated with Oculus Microcyn60 heal with better cosmetic results and less chelation relative to the previous standard burn treatment. Although these results are encouraging, they must be properly evaluated in prospective multicenter clinical trials. Integral to the evaluation of Oculus Microcyn60 must be the impact that its use has on existing infection rates and infectious complications, patient outcomes, costs, and patient satisfaction. Yet, it is encouraging to know that water, even in this advanced form, remains the best method of cleaning a wound. ■

References

1. Dirección General de Epidemiología. Sistema Unico de Información para la Vigilancia Epidemiológica. Información preliminar 2003. México. www.dgepi.salud.gob.mx.
2. Foglia RP, Moushey R, Meadows L, et al. Evolving treatment in a decade of pediatric burn care. *J Pediatr Surg*. 2004;39(6):957–960.
3. Weber JM, Sheridan RL, Pasternack MS, Tompkins RG. Nosocomial infections in pediatric patients with burns. *Am J Infect Control*. 1997;25(3):195–201.
4. Unal S, Ersoz G, Demirkan F, et al. Analysis of skin-graft loss due to infection: infection-related graft loss. *Ann Plast Surg*. 2005;55(1):102–106.
5. Dantzer E, Braye FM. Reconstructive surgery using an artificial dermis (Integra): results with 39 grafts. *Br J Plast Surg*. 2001;54(8):659–664.
6. Nakae H, Inaba H. Effectiveness of electrolyzed oxidized water irrigation in a burn-wound infection model. *J Trauma*. 2000;49(3):511–514.
7. Sekiya S, Ohmori K, Harii K. Treatment of infectious skin defects or ulcers with electrolyzed strong acid aqueous solution. *Artif Organs*. 1997;21(1):32–38.
8. Landa-Solis C, Gonzalez-Espinosa D, Guzman-Soriano B, et al. Microcyn: a novel super-oxidized water with neutral pH and disinfectant activity. *J Hosp Infect*. 2005;61(4):291–299.
9. Meschter C. Safety and Efficacy of Treatment for Cutaneous Wound Study. Comparative Biosciences, Inc. Study Number: 8212-04, 2005.
10. Dalla Paola L, Brocco E, Senesi A, Ninkovic S, Mericvo M, De Vido D. Use of Dermacyn, a new antiseptic agent for the local treatment of diabetic foot ulcers. *J Wound Healing*. 2005;2:201.
11. Martínez de Jesús F. A prospective, randomized, single blinded study with neutral pH-super oxidized water in diabetic patients with infected feet ulcers. Submitted 2005. Unpublished data.